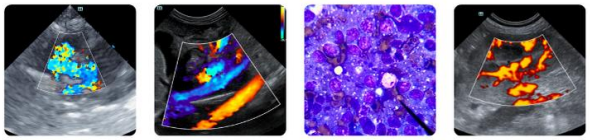



**PATIENT**
Lucas Cochachi

**SPECIES**
Canine

**BREED**
Chihuahua

**SEX**
Male

**AGE**
12.5 years

**WEIGHT**
8.5lbs

**INTERPRETED BY**
Maggie Machen Lamy, DVM, DACVIM (Cardiology)

**IMAGING PERFORMED BY**
Hesham Elakbawy, DVM

**HOSPITAL NAME**
Lincoln Avenue Cat and Dog Hospital

**REFERRING VET**
Dr. Hesham Elakbawy

**INVOICE**
46685

**DATE**
2/4/26

## PRESENTING CLINICAL SIGNS

History: Diagnosed with CHF and mitral valve thickening at EC. Grade 3/6 heart murmur.

## ECHOCARDIOGRAM FINDINGS

Limited 2D, m-mode, color flow and doppler imaging is available. No obvious mitral regurgitation; however, the valve is not adequately interrogated. No left atrial dilation. Normal LV diameter with adequate myocardial function. The right heart appears normal. The pulmonic and aortic valves are normal in morphology and mobility. Normal pulmonic and aortic outflow velocities with laminar flow. No pericardial or pleural effusion noted. No obvious cardiac masses.

## CARDIAC CHART

| CANINE CARDIAC PARAMETERS | MR VMAX (m/s) | TR VMAX (m/s) | LA/AO (Boon method) | LA/AO (Heart Base; Swe) | FS (%) | EF (%) | EPSS (cm) |
|---|---|---|---|---|---|---|---|
| NORMAL PARAMETER | 4.5-5.5 | <2.7 | 1.3 | <1.6 | 28-40 | 40-100 | <0.6 |
| PATIENT | NM | NM | NM | 1.4 | 48 | 90 | NM |
| **CANINE CARDIAC PARAMETERS** | **HR** (BPM) | **AV VMAX** (m/s) | **PV MAX** (m/s) | **BODY WEIGHT** (kg) | **LA** 2D short axis Base view (cm) | **LVIDd** Avg; 2D and m-mode short axis (cm) | **LVIDs** Avg; 2D and m-mode short axis (cm) |
| NORMAL PARAMETER | 50-100 | 0.7-1.7 | 0.7-1.6 | BELOW | BELOW | BELOW | BELOW |
| PATIENT | NM | 0.9 | 0.8 | 3.9 | 2.1 | 2.3 | 1.4 |

*Normal chamber parameters expressed as a mean value (SD)

### BODY WEIGHT DEPENDENT PARAMETERS

***Note: All measurements based upon multi-modal images and methods. An average value is reported.***

Adapted from June Boon, Veterinary Echocardiography, 1998
Rishniw M and Hollis NE, J Vet Intern Med 2000; 14:429-435
Hansson et al, Vet Rad and Ultrasound 2002
Bonagura et al. Echocardiography: principles of interpretation, Vet Clin North Am 15:1177, 1995

| | | | |
|---|---|---|---|
| 3 | 1.27 (5.3) | 2.46 (2.46) | 1.36 (5.5) |
| 5 | 1.40 (4.5) | 2.74 (5.2) | 1.60 (4.7) |
| 10 | 1.50 (3.8) | 3.27 (3.5) | 2.06 (3.1) |
| 15 | 1.83 (2.0) | 3.71 (2.4) | 2.43 (2.1) |
| 20 | 2.02 (1.9) | 4.14 (2.2) | 2.80 (2.0) |
| 25 | 2.18 (2.4) | 4.48 (2.9) | 3.10 (2.5) |
| 30 | 2.33 (3.3) | 4.83 (3.9) | 3.39 (3.4) |
| 35 | 2.48 (4.3) | 5.17 (5.0) | 3.69 (4.5) |
| 40 | 2.62 (5.2) | 5.48 (6.1) | 3.96 (5.4) |
| 50 | 2.88 (7.1) | 6.07 (8.3) | 4.46 (7.4) |

## INTERPRETATION OF THE FINDINGS & FURTHER RECOMMENDATIONS

Limited image set provided. Early chronic degenerative valve disease is suspected; however, without adequate color flow interrogation, this cannot be confirmed. The overall dimensions and function appear intact. Additionally, abnormalities may certainly have been missed, such as pulmonary hypertension.

Even without a complete study, what can be said is CHF is considered unlikely in this case. Follow up should include obtaining previous and current radiographic, potentially referral for advanced evaluation, etc.

Assessment of progression in the future will help predict long term prognosis, which is highly variable at this stage (B1). Omega fatty acid supplementation and mild salt restriction may be of

**PATIENT**

Lucas Cochachi

**SPECIES**

Canine

**BREED**

Chihuahua

**SEX**

Male

**AGE**

12.5 years

**WEIGHT**

8.5lbs

**INTERPRETED BY**

Maggie Machen Lamy, DVM, DACVIM (Cardiology)

**IMAGING PERFORMED BY**

Hesham Elakbawy, DVM

**HOSPITAL NAME**

Lincoln Avenue Cat and Dog Hospital

**REFERRING VET**

Dr. Hesham Elakbawy

**INVOICE**

46685

**DATE**

2/4/26

some long-term benefit. Monitor for development of a cough, labored breathing, exercise intolerance or collapse episodes.

Anesthesia is not advised prior to further evaluation,.

Recommend conservative monitoring with a recheck echocardiogram in 6-12 months, sooner if any development of clinical signs.

**IMAGES**

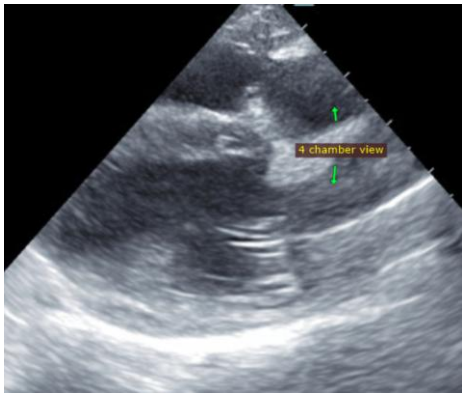


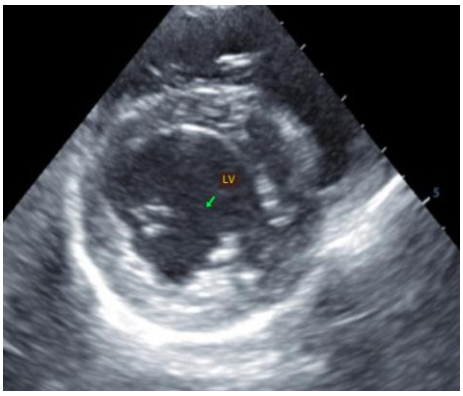


**The information and recommendations provided are based on the images presented by the referring veterinarian. No evaluation can be communicated regarding pathology that was not visible in the image/video clips provided.**

Thank you for this referral. This report was generated using transcription software, and minor dictation errors may be present. If the clinical or image interpretation does not parallel your findings or if I can be of any further assistance, please contact me.

**Maggie Machen Lamy, DVM**
**Diplomate of the American College of Veterinary Internal Medicine (Cardiology)**
info@sonopath.com